

Transient hypogammaglobulinemia of infancy presenting as *Staphylococcus aureus* sepsis with deep neck infection

Kai-Chung Hsueh, Hsiu-Hui Chiu, Hsiao-Chuan Lin, Ching-Hsiang Hsu, Fuu-Jen Tsai

Department of Pediatrics, China Medical University Hospital, Taichung, Taiwan

Received: February 23, 2004 Revised: June 28, 2004 Accepted: July 2, 2004

Transient hypogammaglobulinemia of infancy (THI) is characterized by a prolongation and accentuation of the physiologic hypogammaglobulinemia normally occurring during the first 3 to 6 months of life and recovers spontaneously between 18 and 36 months of age. Infants with THI may remain asymptomatic or develop recurrent sinopulmonary infections, but severe or life-threatening infections are rare. We report a case of THI in a previously healthy 1-year-old girl with *Staphylococcus aureus* sepsis who subsequently developed deep neck infection confirmed by magnetic resonance imaging. Intravenous oxacillin was administered for 21 days and she recovered completely. Immunologic studies were normal except for decreased immunoglobulin G levels. Under the impression of hypogammaglobulinemia with severe infection she received regular intravenous immunoglobulins (IVIG) replacement therapy every 4 weeks. One year later, the immunoglobulin concentrations had returned to the normal range even though IVIG had been discontinued for 4 months. This case report highlights the possibility of severe infection in THI, a disease which usually has a benign clinical course. As the diagnosis of THI can only be made with certainty in retrospect, long-term follow-up of clinical and immune system status is necessary.

Key words: Abscess, IgG deficiency, infant, neck, *Staphylococcus aureus*

Physiologic hypogammaglobulinemia generally occurs between 3 and 6 months of age when maternal immunoglobulin G (IgG) has decreased and the infant's own synthesis is not yet fully developed. Occasionally, onset of adequate immunoglobulin synthesis may be abnormally delayed until between 18 and 36 months of age, resulting in prolonged depression of immunoglobulin levels, a condition defined as transient hypogammaglobulinemia of infancy (THI) [1]. The underlying basis for this disorder is unknown and may be heterogeneous. Infants with THI may have recurrent infections; however, severe or life-threatening infections are extremely rare. We report a rare case of THI presenting as *Staphylococcus aureus* sepsis complicated with deep neck infection.

Case Report

A previously healthy 1-year-old girl with no known history of recurrent infections and no familial history of immunodeficiency was admitted because of high fever for 4 days, vomiting, poor activity and poor appetite

for 2 days. One day earlier she had been sent to another hospital with similar complaints and vancomycin and cefotaxime were given after blood culture was performed.

On admission, the patient was lethargic but arousable. Vital signs were body temperature 38.2°C, pulse rate 155/min, respiratory rate 30/min, and blood pressure 88/52 mm Hg. Physical examination showed visible tonsillar tissues and palpable lymph nodes. The neck was supple and with no apparent pain on movement. There were no mucocutaneous lesions. Laboratory investigations revealed hemoglobin 9.22 g/dL, white blood cell count 20900/mm³ with 81% neutrophils and 9% lymphocytes. Platelet count was 134,000/mm³ and C-reactive protein was 26.58 mg/dL. Erythrocyte sedimentation rate at 1 hour was 56 mm/hour. Coagulopathy was noted with activated partial thromboplastin time of 103.90 seconds (normal, 26.3-34.3 seconds), fibrin degradation product >20 µg/mL (normal, <5 µg/mL), D-dimer 1-2 µg/mL (normal, <0.5 µg/mL). Other laboratory data were unremarkable, including urinalysis and cerebrospinal fluid (CSF) study. Under suspicion of sepsis, vancomycin and meropenem were administered empirically after septic work-up was done. On the third hospital day, both the blood culture performed

Corresponding author: Dr. Hsiao-Chuan Lin, Department of Pediatrics, China Medical University Hospital, 2 Yuh Der Road, Taichung 404, Taiwan.
E-mail: d4267@www.cmuh.org.tw

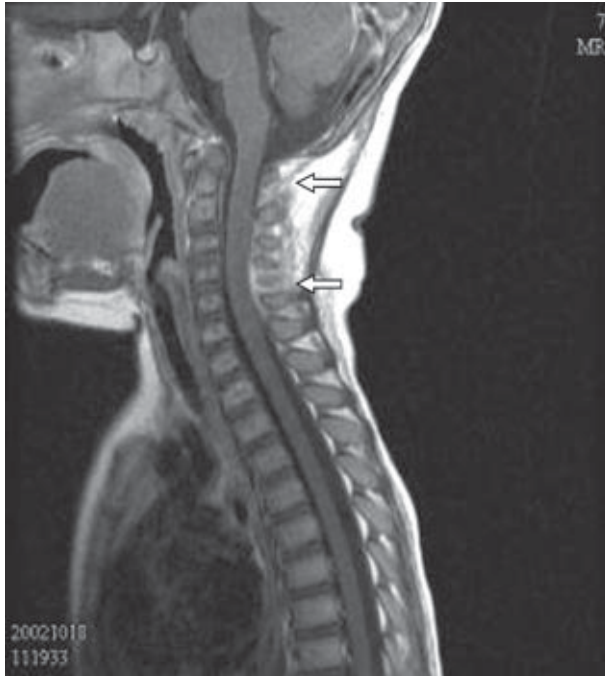

Fig. 1. Sagittal T1-weighted magnetic resonance imaging after intravenous gadolinium-diethylenetriamine pentaacetic acid administration shows abnormal enhancement in the interspinous space at the C2 to C5 level (arrows).

at admission and the blood culture obtained at another hospital yielded *S. aureus* which was susceptible to oxacillin. CSF and urine cultures were negative. Antibiotics were changed to oxacillin and gentamicin. Computed tomography of the brain was arranged due to persistent drowsiness but showed no abnormalities. Her condition improved gradually, except for persistent fever on the 10th day. In addition, irritable crying on movement of the neck with progressive limitation of neck motion developed, while only mild erythema over the posterior neck was noted. Radionuclide scan and echocardiography were arranged to identify the focus of the persistent fever. Echocardiography showed no evidence of vegetation or coronary vascular dilatation. Gallium-67 citrate whole body scan revealed active soft tissue inflammation in bilateral lower neck regions.

On the 14th day of hospitalization, magnetic resonance imaging (MRI) of the cervical spine showed abnormal enhancement in the interspinous space and left paravertebral space at the C2 to C5 level compatible with deep neck infection (Fig. 1 and 2). No evidence of vertebral osteomyelitis or discitis was seen on MRI. Despite defervescence since the 11th day of hospitalization, parenteral antibiotics were administered for 21 days until complete recovery of neck motion and she was discharged in stable condition.

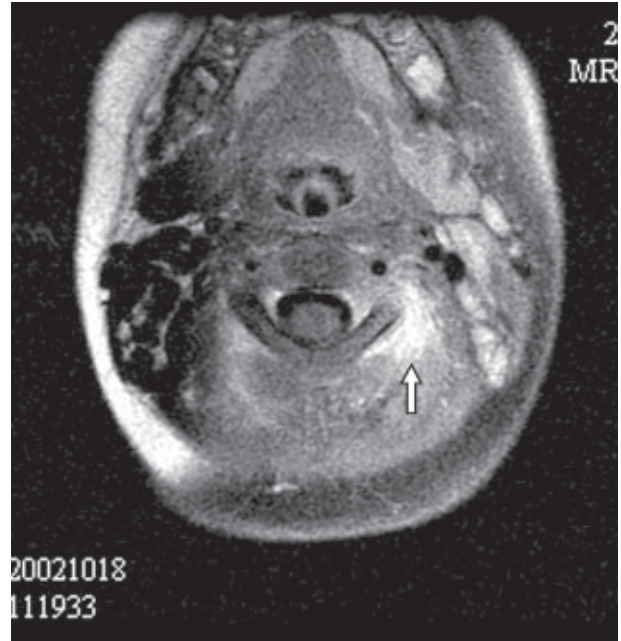


Fig. 2. Axial T1-weighted magnetic resonance imaging at the C2 level with fat signal suppression and after intravenous gadolinium-diethylenetriamine pentaacetic acid administration shows abnormal enhancement in the left paravertebral space (arrow).

Due to sepsis of unknown origin and the isolation of a relatively uncommon microbial organism for a patient of this age, immunologic studies were performed after the antibiotic treatment was completed and the results were as follows: IgG 139 mg/dL (reference, 345-1236 mg/dL); IgA 93.4 mg/dL (reference, 14-159 mg/dL); IgM 183 mg/dL (reference, 43-207 mg/dL); IgE 55.6 IU/mL (reference, 0-200 IU/mL). Lymphocyte subset analysis showed T cells 60%, B cells 22%, CD4⁺ 31%, and CD3⁺:CD8⁺ 30%. Total lymphocyte count was 4876/mm³. The proliferative responses of T cells to phytohemagglutinin and pokeweed mitogen were not different from the control. Nitroblue tetrazolium test and leukocyte chemotaxis assay were normal. Under the initial impression of primary antibody deficiency of THI or common variable immunodeficiency (CVID) with life-threatening infection, she received regular intravenous immunoglobulins (IVIG) replacement therapy of 400 mg/kg every 4 weeks, starting at the age of 13 months. Due to gradual increase of IgG trough levels (Table 1), IVIG was discontinued at age 20 months and serum immunoglobulin concentrations remained within the normal range at follow-up 4 months later (Table 1). After this episode, she had no more life-threatening infection during 2 years of follow-up. These findings confirmed the diagnosis of THI.

Table 1. Serial serum immunoglobulin levels and dosage of intravenous immunoglobulins (IVIg) replacement therapy in an infant with transient hypogammaglobulinemia of infancy

Age	Immunoglobulin G (mg/dL)	Dosage of IVIG replacement ^a
13 months ^b	139	400 mg/kg
15 months	210	400 mg/kg
16 months	303	400 mg/kg
17 months	340	400 mg/kg
18 months	410	400 mg/kg
19 months	518	400 mg/kg
20 months	585	Discontinued
22 months	660	
2 years ^c	810	

^aEach dose of IVIG replacement therapy was given after serum immunoglobulin levels had been checked in each follow-up.

^bImmunoglobulin A and immunoglobulin M values at 13 months were 93.4 and 183 mg/dL, respectively.

^cImmunoglobulin A and immunoglobulin M values at 2 years were 83 and 110 mg/dL, respectively.

Discussion

THI was first described by Gitlin and Janeway in 1956 [1]. It has been defined classically as a prolongation and accentuation of the physiologic hypogammaglobulinemia normally occurring during the first 3 to 6 months of life. Spontaneous recovery occurs between 18 and 36 months of age. The incidence of THI is unknown. Although Tiller and Buckley reported that THI is rather uncommon [2], a nationwide survey in Japan indicated that the disorder was evident in 18.5% of all patients with primary immunodeficiency disorders [3]. The causes of THI remain unclear. A previous study described deficiency of helper T cells [4], but this has not been confirmed by others [2,5,6]. Although the World Health Organization Scientific Group on Primary Immunodeficiency includes diminished IgG and IgA levels in its definition of THI [7], the frequency with which different isotypes have been diminished varies from one report to another. Diminished values of IgG are generally considered to be an invariant feature of THI [5]. In contrast, the incidence of diminished IgA and IgM concentrations has ranged from 0% to 100% and 14% to 63% in different reports [4,8]. In spite of this relative hypogammaglobulinemia, the numbers of B and T cells and T-cell responses to mitogens are normal [2,5,6,9]. Isohemagglutinin titers and specific antibody response after immunization are generally in the normal range [2,5,8].

McGeady found that acquisition of normal immunoglobulin levels was delayed beyond infancy in

some cases, and usually resolved at 2-5 years of age [8]. Moreover, McGeady's study as well as a study by Tiller and Buckley [2] found that a subgroup of THI patients did not recover from hypogammaglobulinemia and later developed selective IgA deficiency or other dysgammaglobulinemia. Based on these findings, McGeady argued that the name and definition of THI needs to be reconsidered and the alternative designation "hypogammaglobulinemia of early childhood" was suggested [8]. These findings indicate the importance of long-term follow-up. Indeed, by definition, the diagnosis of transient hypogammaglobulinemia cannot be established with certainty until after the child's immunoglobulin levels have reached age-appropriate levels. Until that time, every effort should be made to differentiate THI from other more severe forms of primary humoral immunodeficiency such as X-linked agammaglobulinemia (XLA) and CVID. Serum immunoglobulin concentrations, particularly of IgA and IgM, are usually considerably lower in XLA and CVID patients than in patients with THI. In addition, one of the distinguishing characteristics of THI is a normal capacity to synthesize specific antibodies in response to immunization, a feature that allows easy distinction of THI from XLA and CVID. Unfortunately, we failed to test specific antibodies in this patient.

The clinical manifestations of THI vary from patients who are free from any symptoms to others with recurrent infections [2,10]. However severe or life-threatening infections, such as sepsis or meningitis, have rarely been reported [11-13]. Individuals with defective chemotaxis, defective phagocytosis and defective humoral immunity (antibodies required for opsonization), as well as those with an impaired intracellular bactericidal capacity, are at increased risk of infection with staphylococci. Staphylococcal bacteremia is rarely recognized in the absence of a focus of infection. The focus may be inapparent or exceedingly minor. In this case, the portal of entry of this organism could not be determined by physical examination and clinical history. The deep neck infection was thought to represent seeding of the organism to the involved soft tissues during bacteremia because the symptoms and signs in the neck developed progressively only days after admission. Staphylococcal sepsis may localize subsequently at any site but is most commonly found in the lungs, heart, joints, bones and brain. The involvement of neck soft tissues is extremely rare. This finding in conjunction with the relatively uncommon isolate in occult bacteremia of infancy prompted us to survey the immune status in this patient.

In general, supportive therapy and appropriate antimicrobial therapy for specific infections are sufficient management in patients with THI. Although immunoglobulin replacement therapy is generally not warranted, in cases of infections which are severe or refractory to conventional management, immunoglobulin therapy is sometimes considered on a temporary basis. Short-term use of immunoglobulin infusions in one study did not appear to delay the spontaneous resolution of THI [14].

While THI is a self-limited disorder and usually has a benign clinical course, severe infections may still occur. Moreover, one should bear in mind that THI remains a diagnosis that can only be established with certainty in retrospect. Thus, long-term follow-up and frequent re-evaluation of the child's clinical status and immune system are necessary.

References

1. Gitlin D, Janeway CA. Agammaglobulinemia, congenital, acquired, and transient forms. *Prog Hematol* 1956;1: 318-29.
2. Tiller TL Jr, Buckley RH. Transient hypogammaglobulinemia of infancy: review of the literature, clinical and immunologic features of 11 new cases, and long-term follow-up. *J Pediatr* 1978;92:347-53.
3. Hayakawa H, Iwata T, Yata J, Kobayashi N. Primary immunodeficiency syndrome in Japan. I. Overview of a nationwide survey on primary immunodeficiency. *J Clin Immunol* 1981;1:31-9.
4. Siegel RL, Issekutz T, Schwaber J, Rosen FS, Geha RS. Deficiency of T helper cells in transient hypogammaglobulinemia of infancy. *N Engl J Med* 1981;305:1307-13.
5. Dressler F, Peter HH, Müller W, Rieger CH. Transient hypogammaglobulinemia of infancy: Five new cases, review of the literature and redefinition. *Acta Paediatr Scand* 1989;78: 767-74.
6. Kilic SS, Tezcan I, Sanal O, Metin A, Ersoy F. Transient hypogammaglobulinemia of infancy: clinical and immunologic features of 40 new cases. *Pediatr Int* 2000;42:647-50.
7. World Health Organization. Primary immunodeficiency diseases: report of a WHO scientific group. *Immunodeficiency Rev* 1992;3:195-236.
8. McGeady SJ. Transient hypogammaglobulinemia of infancy: need to reconsider name and definition. *J Pediatr* 1987;110: 47-50.
9. Rieger CH, Nelson LA, Peri BA, Lustig JV, Newcomb RW. Transient hypogammaglobulinemia of infancy. *J Pediatr* 1977; 91:601-03.
10. Rosen FS, Cooper MD, Wedgwood RJ. The primary immunodeficiencies. (2). *N Engl J Med* 1984;311:300-10.
11. Simon JL, Bosch J, Puig A, Grau M. Two relapses of group B streptococcal sepsis and transient hypogammaglobulinemia. *Pediatr Infect Dis J* 1989;8:729-30.
12. Smart JM, Kemp AS, Armstrong DS. *Pneumocystis carinii* pneumonia in an infant with transient hypogammaglobulinemia of infancy. *Arch Dis Child* 2002;87:449-50.
13. Kosnik EF, Johnson JP, Rennels MB, Caniano DA. Streptococcal sepsis presenting as acute abdomen in a child with transient hypogammaglobulinemia of infancy. *J Pediatr Surg* 1986;21:975-6.
14. Cano F, Mayo DR, Ballow M. Absent specific viral antibodies in patients with transient hypogammaglobulinemia of infancy. *J Allergy Clin Immunol* 1990;85:510-3.