

# Non-septicemic *Burkholderia pseudomallei* liver abscess in a young man

Ren-Jy Ben<sup>1</sup>, Yuh-Yuan Tsai<sup>2</sup>, Jyh-Ching Chen<sup>3</sup>, Nan-Hsiung Feng<sup>1</sup>

Divisions of <sup>1</sup>Infectious Diseases and <sup>2</sup>Gastroenterology, Department of Internal Medicine; and  
<sup>3</sup>Department of Radiology, Kaohsiung Military General Hospital, Kaohsiung, Taiwan, ROC

Received: September 1, 2003 Revised: October 20, 2003 Accepted: October 27, 2003

Melioidosis, caused by *Burkholderia pseudomallei*, has been increasingly recognized in Taiwan recently. Its isolation in liver abscess is rare compared to pulmonary melioidosis. We report a case of liver abscess due to *B. pseudomallei* in an immunocompetent 27-year-old male soldier admitted due to fever, sore throat and mild non-productive cough for 1 week. Physical examination was unremarkable except for congestion of the pharyngeal wall, moderate enlargement of the tonsils without pus coating, and palpable tender lymphadenopathy over bilateral submental regions. Antibiotic treatment with cefazolin 1 g every 8 hours intravenously was given without response. Left flank pain, followed by right flank pain associated with epigastric tenderness developed. Sonography and computed tomography scan of the abdomen demonstrated liver abscess. Aspiration of the liver abscess was performed and abscess culture yielded *B. pseudomallei*. Treatment with ceftazidime 2 g every 8 hours intravenously (4 weeks' duration) followed by oral regimens of amoxicillin-clavulanate was given. The patient was free of symptoms at 8 months' follow-up. Early awareness and definite diagnosis as well as institution of proper antimicrobial agents are imperative for successful treatment of melioidosis.

**Key words:** *Burkholderia pseudomallei*, case reports, liver abscess, melioidosis

Melioidosis is caused by *Burkholderia pseudomallei*, a ubiquitous bacteria found in damp soil and fresh water in many parts of the tropics. The usual mode of acquisition is probably by inoculation, with bacteria presumably entering the body through minor skin abrasions or by inhalation [1]. Melioidosis has been reported throughout the world between 20 degrees north and south latitudes, with the main endemic area being Southeast Asia and northern Australia [2]. Melioidosis was first reported as an imported case from the Philippines in 1985 [3]. Domestically acquired melioidosis was first reported by Lee et al in 1996 [4]. Sporadic cases were reported subsequently, mostly presenting as pulmonary melioidosis [5-8]. Taiwan should be included as an endemic area for melioidosis as three-quarters of infections were considered indigenous in a recent survey by Hsueh et al [9]. Melioidosis presents in a variety of forms ranging from localized abscess to fulminant septicemia [1]. Although several organs may be involved in melioidosis, pulmonary infection is the most common form [2]. Liver

abscess characterized by multiple hypoechoic areas on ultrasonography was significantly associated with melioidosis [10]. We report an indigenous melioidosis presenting as non-septicemic liver abscess. The patient recovered after antibiotic treatment.

## Case Report

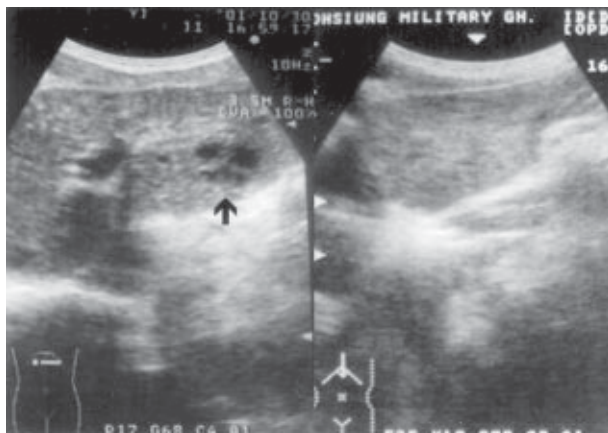
A 27-year-old male soldier was admitted to the emergency room on October 18, 2001 due to fever, sore throat and mild non-productive cough for 1 week. He resided in Tainan county, South Taiwan and had no history of traveling abroad. He had a history of acute tonsillitis with fever about 5 months prior to this admission. He had experienced minor abrasions over both hands 2 weeks prior to this admission due to catching fish in a pond. His abrasive wounds had healed well spontaneously. He had smoked cigarettes, 1 package per day, for 6-7 years and occasionally drank socially. Vital signs on admission included blood pressure 106/40 mm Hg, pulse rate 97/min, respiratory rate 20/min, and body temperature 38.7°C. Physical examination was unremarkable except for congestion of the pharyngeal wall, moderately enlarged tonsils without pus coating, and palpable tender

---

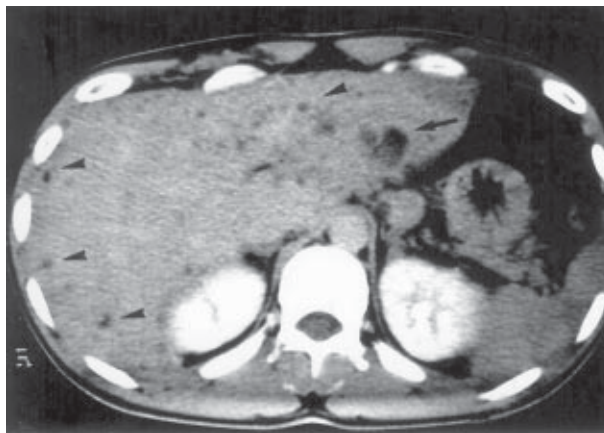Corresponding author: Dr. Ren-Jy Ben, Division of Infectious Diseases, Department of Internal Medicine, Kaohsiung Military Hospital, 2, Chung-Chen 1st Road, Kaohsiung, 802, Taiwan, ROC.  
E-mail: m9121304@student.nsysu.edu.tw

lymphadenopathy over bilateral submental regions. He had no demonstrable wounds over his hands. Hemogram showed a white blood cell count of  $12,300/\text{mm}^3$  with 79.7% neutrophils, 9.3% lymphocytes and 9.6% monocytes, hemoglobin of 13.2 g/dL, hematocrit of 39.8%, and platelet count of  $311,000/\text{mm}^3$ . Erythrocyte sedimentation rate was 56 mm/hour, and C-reactive protein was 7.765 mg/dL. Urinalysis was normal. Blood biochemistry showed normal results. Chest roentgenogram showed increased bilateral bronchovascular markings. He was treated with cefazolin 1 g every 6 hours intravenously, but clinical response was poor. Erythromycin 500 mg 4 times a day orally was replaced and cefazolin was discontinued on day 5 under suspicion of mycoplasmal pneumonia due to *Mycoplasma immunoglobulin M* titer of 1:80. On day 12, he was still febrile and experienced sore throat and pain over the epigastric region and both flank regions, congestion of the pharynx, and hypertrophy of bilateral tonsils with some exudate as well as palpable tender lymph nodes over bilateral submental regions. Abdominal sonography showed a poorly demarcated, hypoechoic lesion over the left hepatic lobe (Fig. 1) and multiple cystic lesions measuring 0.5 to 0.8 cm over the right hepatic lobe. Computed tomography (CT) scan of the abdomen showed a heterogeneous hypodense lesion about 2.5 cm over the left lobe of the liver, and diffuse tiny homogeneous hypodense lesions over both lobes of liver (Fig. 2).

Under sonographic guidance, needle aspiration of the hepatic lesion was performed, which yielded about 0.5 mL purulent fluid. Few Gram-negative bacilli were identified on microscopic examination of the specimen.



**Fig. 1.** Abdominal sonography in the axial view (left) shows the liver abscess as a hypoechoic lesion (arrow) over the left lobe. Lesional remission is apparent on sonography (right) performed 3 months later.



**Fig. 2.** Computed tomography scan of abdomen shows a heterogeneous hypodense lesion about 2.5 cm over the left lobe of the liver, segment 3 (arrow), and diffuse tiny homogeneous hypodense lesions over both lobes of the liver (arrowheads).

Cefazolin 1 g every 6 hours intravenously and metronidazole 500 mg every 6 hours intravenously were prescribed thereafter. Serology was positive for hepatitis B surface antigen, but amebiasis antibody, anti-hepatitis C virus, CEA, AFP and CA19-9 were within normal limits. Acid-fast stain and mycobacterial culture for sputum and gastric fluid were negative. Two sets of blood cultures on day 1 and 2 on day 12 were all negative. Pus culture was performed by the AutoSCAN-4 (MicroScan, Dade International Inc., West Sacramento, CA, USA) identification system and yielded *B. pseudomallei*, which was sensitive to amoxicillin-clavulanate, ceftazidime, ceftriaxone, piperacillin, chloramphenicol, imipenem, and ciprofloxacin. Minimum inhibitory concentrations of ceftazidime and amoxicillin-clavulanate for *B. pseudomallei* were determined by E-test (AB Biodisk, Solna, Sweden) with the same levels of 4 mg/mL. Liver abscess due to *B. pseudomallei* was diagnosed. The antibiotic regimen was changed to ceftazidime 2 g every 8 hours intravenously on hospital day 19. His fever subsided on hospital day 37. Diarrhea was noted since hospital day 25 and persisted for 2 weeks. Several stool specimens were negative for bacterial cultures, ova and parasites. Parenteral antibiotics were discontinued after 4 weeks of treatment followed by oral antibiotics with amoxicillin-clavulanate 500/125 mg, 2 tablets 3 times a day. He was discharged after a total hospital stay of 54 days with stable condition including resolution of submental lymphadenopathy. Oral antibiotics were maintained for 6 weeks after discharge. Abdominal sonography showed disappearance of the hypoechoic lesion in the left lobe of the liver at the outpatient clinic 3 months after his discharge from hospital (Fig. 1).

## Discussion

*B. pseudomallei* is a small, Gram-negative, motile, aerobic bacillus with safety pin bipolar staining on Wright stain, and characteristic wrinkling of the colonies after 72 hours or longer on culture media [2]. At least 3 manifestations of melioidosis, including acute, subacute and chronic forms have been distinguished. Symptoms vary from pneumonia to abscesses of various organs and tissues, including the skin [11]. The clinical features ranged from disseminated septicemia (45%), localized septicemia (42%), non-disseminated septicemia (12%), and rarely, transient bacteremia (0.3%) [12]. Our patient presented with febrile illness with initial manifestations of bronchopneumonia and tonsillitis. The lack of identification of a definite etiology of the purulent tonsillitis during the clinical course, the patient's prior history of this condition and its resolution during antibiotic treatment, suggest it was a concurrent condition which was not related to the melioidosis. In this patient, liver abscess was diagnosed by sonography and CT scan of the abdomen with characteristic findings suggestive of melioidosis [10].

Bacteria presumably enter the body through minor skin abrasions, although inhalation may also occur [1]. A series of observations regarding the ecology of *B. pseudomallei* revealed that infections often followed exposure to contaminated soil and muddy water of ponds and rice paddies [13]. Therefore, it may be speculated that the possible mode of transmission in this patient was due to contamination with infectious soil and water through his skin abrasions sustained when he tried to catch a fish in a pond.

The ultrasonographic features that suggested melioidosis were multiple small cavities in the liver parenchyma — i.e., “Swiss cheese” abscess, and associated visceral abscesses in other organs, with spleen being the most common site of concurrent abscess [10]. However, this patient had no splenic involvement and his liver abscess had healed at 3 months after discharge as shown by abdominal sonography. This finding is comparable to results illustrated by Wibulpolprasert and Dhiansiri in which the liver and spleen abscesses required 2 weeks to 1 year to heal [14].

*B. pseudomallei* can survive and multiply in phagocytes and is a facultative intracellular bacteria, which may be the cause of the difficulty of treatment despite the effectiveness of antimicrobial agents against the organism in vitro [15]. The deep-seated visceral abscess formation in this patient may also explain the protracted course of

febrile illness and dull response to therapy even though effective antibiotics were administered. The optimum duration of treatment is unknown, but it is optional to give intravenous and then oral antimicrobial therapy for 6 weeks to 4 months depending on the site of infection [16]. Maintenance treatment courses are clearly insufficient for severe diseases [17].

Even if the organism shows in vitro sensitivity to the drug used, lack of response to chemotherapy is common in the disseminated septicemic form of melioidosis; therefore, a large dose of each antibiotic is suggested in order to achieve adequate serum inhibitory and bactericidal concentrations [11]. Ceftazidime treatment was associated with 50% lower overall mortality than conventional treatment (chloramphenicol, tetracycline and trimethoprim-sulfamethoxazole) and was therefore recommended as the treatment of choice for severe melioidosis [18]. Parenteral amoxicillin-clavulanate was shown to be as effective as ceftazidime in severe melioidosis in an open randomized controlled study, but parenteral ceftazidime remains the treatment of choice for severe melioidosis [19]. Initial parenteral treatment with ceftazidime reduced the risk of relapse in patients with severe diseases or associated conditions or in immunocompromised hosts [11,17]. This patient became afebrile 16 days after appropriate parenteral antibiotic treatment, which was switched to oral antibiotics after a period of 4 weeks.

Pretreatment with antibiotics active against *B. pseudomallei* did not appear to interfere with culture results, but may interfere with results of cultures for other pathogens [10]. Although various stimuli such as operative procedures, burns and other types of stress can cause activation of the disease [20], confirmation of the diagnosis of melioidosis by using percutaneous needle aspiration under sonographic guidance and after administration of a parenteral antimicrobial agent was a safe and effective method [10]. Despite the protracted course of febrile illness, the diseases in this patient should be classified as non-septicemic localized melioidosis because neither infected foci beyond the liver nor bacteremia was found. The favorable outcome with adequate treatment was thus predictable. In conclusion, early awareness and definite diagnosis as well as institution of proper antimicrobial agents for treating melioidosis are imperative.

## References

1. Kanaphun P, Thirawattanasuk N, Suputtamongkol Y, Naigowit P, Dance DA, Smith MD, et al. Serology and carriage of

- Pseudomonas pseudomallei*: a prospective study in 1000 hospitalized children in Northeast Thailand. *J Infect Dis* 1993; 167:230-3.
2. Sanford JP. *Pseudomonas* species (including melioidosis and glanders). In: Mandell GL, Bennett JE, Dolin R, eds. Principles and practice of infectious diseases. 4th ed. New York: John Wiley & Son Inc.; 1995:2003-8.
  3. Lee N, Wu JL, Lee CH, Tsai WC. *Pseudomonas pseudomallei* infection from drowning: the first reported case in Taiwan. *J Clin Microbiol* 1985;23:352-4.
  4. Lee SS, Liu YC, Chen YS, Wann SR, Wang JH, Yen MY, et al. Melioidosis: two indigenous cases in Taiwan. *J Formos Med Assoc* 1996;95:562-6.
  5. Tsai WC, Liu YC, Yen MY, Wang JH, Chen YS, Wang JH, et al. Septicemic melioidosis in southern Taiwan: a case report. *J Microbiol Immunol Infect* 1998;31:137-40.
  6. Chiu KL, Hsia TC, Hang LW, Yang S. Masking the diagnosis of melioidosis in initial response to penicillin-a case report from mid-Taiwan. *Thorac Med* 2001;16:179-82.
  7. Huang HC, Lee HC, Lee CH, Chen CW. Pulmonary melioidosis-a case report. *Thorac Med* 2001;16:271-6.
  8. Chen YH, Peng CF, Hwang KP, Tsai JJ, Lu PL, Chen TP. An indigenous melioidosis:a case report. *Kaohsiung J Med Sci* 1999;15:292-6.
  9. Hsueh PR, Teng LJ, Lee LN, Yu CJ, Yang PC, Ho SW, et al. Melioidosis: an emerging infection in Taiwan? *Emerg Infect Dis* 2001;7:428-33.
  10. Vatcharapreechasakul T, Suputtamongkol Y, Dance DA, White NJ. *Pseudomonas pseudomallei* liver abscesses: a clinical, laboratory, and ultrasonographic study. *Clin Infect Dis* 1992; 14:412-7.
  11. Brundage WG, Thuss CJ Jr, Walden DC. Four fatal cases of melioidosis in U.S. soldiers in Vietnam. Bacteriologic and pathologic characteristics. *Am J Trop Med Hyg* 1968;17:183-91.
  12. Leelarasamee A, Bovornkitti S. Melioidosis: review and update. *Rev Infect Dis* 1989;11:413-25.
  13. Dance DA. Ecology of *Burkholderia pseudomallei* and the interactions between environmental *Burkholderia* spp. and human-animal hosts. *Acta Tropica* 2000;74:159-68.
  14. Wibulpolprasert B, Dhiensiri T. Visceral organ abscesses in melioidosis: sonographic findings. *J Clin Ultrasound* 1999;27: 29-34.
  15. Pruksachartvuthi S, Aswapokee N, Thankerngpol K. Survival of *Pseudomonas pseudomallei* in human phagocytes. *J Med Microbiol* 1990;31:109-14.
  16. Chaowagul W, White NJ, Dance DA, Wattanagoon Y, Naigowit P, Davis TM, et al. Melioidosis: a major cause of community-acquired septicemia in Northeastern Thailand. *J Infect Dis* 1989; 159:890-9.
  17. Chaowagul W, Suputtamongkol Y, Dance DA, Rajchanuvong A, Pattara-arechachai J, White NJ. Relapse in melioidosis: incidence and risk factors. *J Infect Dis* 1993;168:1181-5.
  18. White NJ, Dance DA, Chaowagul W, Wattanagoon Y, Wuthiekanun V, Pitakwatchara N. Halving of mortality of severe melioidosis by ceftazidime. *Lancet* 1989;2:679-701.
  19. Suputtamongkol Y, Rajchanuwong A, Chaowagul W, Dance DA, Smith MD, Wuthiekanun V, et al. Ceftazidime vs. amoxicillin/clavulanate in the treatment of severe melioidosis. *Clin Infect Dis* 1994;19:846-53.
  20. Piggott JA, Hochholzer L. Human melioidosis. A histopathologic study of acute and chronic melioidosis. *Arch Pathol* 1970;90:101-11.