

# Clinical features of influenza A and B in children and association with myositis

Jen-Jan Hu<sup>1</sup>, Chuan-Liang Kao<sup>2</sup>, Ping-Ing Lee<sup>3</sup>, Chung-Ming Chen<sup>3</sup>, Chin-Yun Lee<sup>3</sup>, Chun-Yi Lu<sup>3</sup>, Li-Min Huang<sup>3</sup>

<sup>1</sup>Department of Pediatrics, Taiwan Adventist Hospital, Taipei; and Departments of <sup>2</sup>Laboratory Medicine and <sup>3</sup>Pediatrics, National Taiwan University Hospital, Taipei, Taiwan, ROC

Received: May 1, 2003 Revised: June 3, 2003 Accepted: July 14, 2003

Influenza virus is among the most common causes of respiratory illness, which may manifest as a range of conditions, from mild upper respiratory tract infection to bronchiolitis and pneumonia. Acute childhood myositis associated with influenza occurs mostly in influenza B infection. In this retrospective study, we analyzed the characteristics of 197 children with influenza virus treated from January 2000 to December 2001. Among them, 73 children had influenza A infection and 124 had influenza B infection. Influenza A virus outbreaks occurred in January 2000, July 2001, and December 2001, while influenza B virus outbreaks occurred from March 2000 to May 2000 and from December 2000 to February 2001. The most common clinical manifestations of influenza A and influenza B virus infection included fever, cough, and rhinorrhea. These infections also frequently manifested as laryngo-tracheobronchitis, pneumonia, and unexplained fever, which led to hospitalization. The most common clinical diagnosis was upper respiratory tract infection. The rates of benign acute childhood myositis in influenza A and influenza B were 5.5% and 33.9%, respectively. Creatine kinase levels were elevated in most myositis cases and boys were more commonly affected. Acute childhood myositis was more commonly seen in influenza B infection.

**Key words:** Child, influenza, myositis

Influenza virus infections are acute, usually self-limited febrile illnesses that occur in outbreaks of variable severity almost every winter in the Northern hemisphere. They are important agents of human respiratory tract diseases in childhood [1]. The spectrum of clinical manifestations of influenza virus infections in children is broad, the most common being fever, cough, and headache. Influenza virus infections might also manifest as a range of illnesses, from mild upper respiratory tract infection to bronchiolitis and pneumonia [2]. While the clinical manifestations of influenza A and B are similar, influenza A is generally more severe and requires hospitalization more frequently [3].

Benign acute childhood myositis associated with influenza is mostly seen in influenza B infections [4-14]. It usually occurs in the early convalescent phase of a typical influenza illness. Severe pain and tenderness in the calves of both legs often occur suddenly with difficulty walking. Elevations of serum creatine kinase and aspartate aminotransferase are characteristic. The purpose of this study was to compare the clinical features

of influenza A and B and to evaluate their associations with myositis.

## Patients and Methods

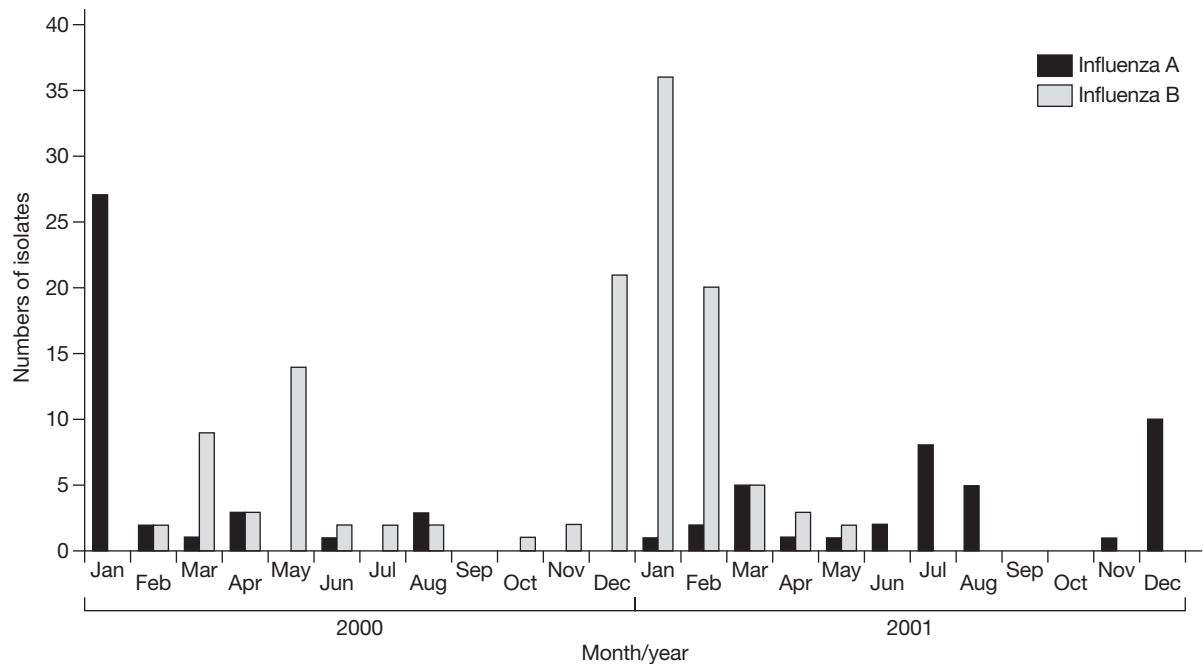
This retrospective study included all 197 children at our institutions with a diagnosis of influenza based on virus culture from January 2000 to December 2001. Data on the clinical manifestations of the illness, including age and gender distribution, common clinical presentations, clinical diagnoses, and their associations with myositis were collected by chart review. Analysis of variance and Student's *t* test were used to compare differences in continuous variables between groups. Chi-squared test and Fisher's exact test were used to compare categorical data.

## Results

There were 73 children with influenza A infection and 124 with influenza B infection. Influenza A infection was diagnosed in 51 boys (70%) and influenza B infection in 78 boys (63%). The mean ages of children with influenza A and influenza B infection were 4 years and 6 years, respectively.

---

Corresponding author: Dr. Li-Min Huang, Division of Infectious Diseases, Department of Pediatrics, National Taiwan University Hospital, No. 7, Chung-Shan South Road, Taipei, Taiwan 100, ROC. E-mail: lmhuang@ha.mc.ntu.edu.tw



**Fig. 1.** Monthly distribution of influenza A and B infections, January 2000 to December 2001.

**Epidemiology**

As shown in Fig. 1, there were 3 outbreaks during the study period, occurring in January 2000, July 2001, and December 2001, respectively. Influenza B virus outbreaks occurred from March 2000 to May 2000, and from December 2000 to February 2001. Infections were most prevalent in the winter and spring seasons, although influenza A outbreaks also occurred in the summer of 2001.

**Clinical findings**

Fever, cough, and rhinorrhea were the most frequent symptoms in influenza A and B infections (Table 1). Other

**Table 1.** Clinical manifestations of influenza infection in children

Symptom/sign	Influenza A n = 73 (%)	Influenza B n = 124 (%)
Fever	72 (98.6)	120 (96.8)
Cough	70 (95.9)	113 (91.1)
Rhinorrhea	49 (67.1)	75 (60.5)
Sore throat	6 (8.2)	14 (11.3)
Hoarseness	8 (11.0)	9 (7.3)
Headache	7 (9.6)	18 (14.5)
Vomiting	12 (16.4)	18 (14.5)
Diarrhea	9 (12.3)	10 (8.0)
Calf pain <sup>a</sup>	4 (5.5)	42 (33.9)

<sup>a</sup>Significantly more frequent in influenza B ( $p < 0.05$ , Fisher's exact test).

symptoms included sore throat, hoarseness, headache, vomiting, diarrhea, and calf pain. The incidences of clinical symptoms in influenza A and B infections were not different, except for the incidence of calf pain, which was much higher in influenza B infections.

**Clinical diagnosis**

The most common clinical diagnosis in influenza A and B infection was upper respiratory tract infection. Other diagnoses in this series included exudative tonsillitis, hand-foot-mouth disease/herpangina, pharyngo-conjunctival fever, and unexplained fever (Table 2). The complications of influenza included sinusitis, acute otitis media, bronchitis, pneumonia, myositis, and central nervous system (CNS) infection (Table 3). Pneumonia and acute otitis media were the most common

**Table 2.** Clinical diagnoses in children with influenza virus infection

	Influenza A n = 73	Influenza B n = 124
Uncomplicated URI	38	79
Exudative tonsillitis	0	4
HFM disease or herpangina	1	1
PCF	1	3
Unexplained fever	1	4

Abbreviations: URI = upper respiratory tract infection; HFM = hand-foot-mouth; PCF = pharyngo-conjunctival fever

**Table 3.** Complications of influenza infection in children

	Influenza A n = 73 (%)	Influenza B n = 124 (%)
Acute otitis media	7 (9.6)	11 (8.9)
Sinusitis	2 (2.7)	2 (1.6)
Croup	9 (12.3)	6 (4.8)
Bronchitis/bronchiolitis	6 (8.2)	8 (6.5)
Pneumonia <sup>a</sup>	15 (20.5)	9 (7.3)
Aseptic meningitis	1 (1.4)	1 (0.8)
Encephalitis	2 (2.7)	2 (1.6)
Myositis <sup>b</sup>	4 (5.5)	42 (33.9)

<sup>a</sup>Significantly more frequent in influenza A ( $p < 0.05$ , Fisher's exact test).

<sup>b</sup>Significantly more frequent in influenza B ( $p < 0.05$ , Fisher's exact test).

complications. Aseptic meningitis and encephalitis were also observed in the study.

### Benign acute childhood myositis

Benign acute childhood myositis was identified in 46 children. Four of these cases were associated with influenza A and 42 with influenza B. The mean age of benign acute childhood myositis patients was 6.5 years. The rates of benign acute childhood myositis in influenza A and influenza B were 5.5% and 33.9%, respectively. Creatine kinase (CK) levels were elevated in all 25 patients with myositis who had data available. The creatine kinase levels ranged from 201 to 6026 U/L. There was no difference in CK levels and duration of myositis between boys and girls. Influenza-associated myositis was more frequent in boys (63%).

### Discussion

Influenza viruses can cause an acute, self-limited febrile illness and occur in outbreaks almost every winter in the Northern hemisphere. Typical infections begin with predominantly systemic symptoms and include fever, chills, headache, myalgia, malaise, and anorexia [3]. A variety of complications associated with influenza are well recognized, including pulmonary complications (primary viral pneumonia with or without secondary bacterial infection, croup, bronchitis, and bronchiolitis) and non-pulmonary complications (myositis, myocarditis, and Reye's syndrome) [2,3]. Some infants with influenza first present with apneic episodes or with a syndrome similar to neonatal sepsis [15,16].

In this series, the most common clinical diagnosis in influenza A and influenza B infection was upper respiratory tract infection. Other diagnoses in this

series included exudative tonsillitis, hand-foot-mouth disease/herpangina, pharyngo-conjunctival fever, and unexplained fever. Unexplained fever included young infant fever and neutropenic fever. The complications of influenza are sinusitis, acute otitis media, bronchitis, pneumonia, myositis, and CNS complications. Sinusitis and acute otitis media were the most common bacterial complications. The most frequent diagnoses for children hospitalized with influenza virus infection are viral and/or bacterial pneumonia, bronchitis, laryngo-tracheobronchitis (croup), CNS syndrome, and unexplained fever [2].

A child may occasionally present with vomiting and/or diarrhea suggestive of gastroenteritis in association with influenza, although the pathogenesis of such symptoms is unclear. Gastrointestinal complaints, including abdominal pain, diarrhea, and vomiting are quite frequent in the younger age group [17]. In this series, the incidences of gastrointestinal symptoms was not different in patients with influenza A and B infections (Table 1).

Benign acute childhood myositis was first described in 1957 by Lundberg under the name of "Myalgia Cruris Epidemica" [4]. In 1970, Middleton et al described 26 cases with elevated CK levels and an association with influenza B infection [5]. Benign acute childhood myositis is characterized by the sudden onset of calf pain and inability or difficulty to walk, often developing within 1 to 5 days after a prodromal viral upper respiratory illness. It is completely distinct from the myalgia in the early stage of influenza, which is usually diffuse and tends to precede or accompany the influenza infection.

In this series, the rates of benign acute childhood myositis in influenza A and influenza B were 5.48% and 33.87%, respectively. Serum creatine kinase (CK) was usually elevated and ranged from 201 to 6026 U/L. Benign acute childhood myositis affects boys more frequently [18]. In this study, 63% of benign acute childhood myositis patients were boys. The condition was generally self-limited and usually persisted for less than a week.

Rhabdomyolysis with myoglobinuria and acute renal failure associated with influenza A have been reported in severe cases in adults [19,20]. No rhabdomyolysis with myoglobinuria or acute renal failure was noted in this series. There is some evidence that this syndrome represents a primary influenza infection, as it primarily occurs in childhood and most patients lack detectable acute phase antibodies [6].

Recently, influenza virus antigens have been detected in muscle biopsies from patients, and influenza A and B viruses were isolated from muscle tissue,

indicating that these viruses can infect muscle in situ [21-24]. The differences between influenza A and B viruses might explain the more common occurrence of myositis in association with influenza B infection. Both influenza A and B viruses have a segmented single-stranded RNA genome. One RNA segment (segment 6) of influenza B virus encodes a small glycoprotein (NB) that appears to be unique to influenza B. The NB protein is an integral component of the membrane of the influenza B virion. The similarities between NB of influenza B and M2 of influenza A viruses in structural features, their presence in the virion and possession of an ion channel activity suggest that NB may have a role in virus entry [25,26]. This NB glycoprotein may render the influenza B virus more myotropic than influenza A. This hypothesis, however, remains to be tested.

## Conclusions

Influenza is an acute, self-limited febrile respiratory illness with predominantly systemic symptoms, including fever, cough, and rhinorrhea. The most common clinical diagnosis in this series was upper respiratory tract infection. Complications associated with influenza include pulmonary complications (primary viral pneumonia with or without secondary bacterial infection, croup, bronchitis, and bronchiolitis) and non-pulmonary complications (myositis, myocarditis, aseptic meningitis, and encephalitis). The rates of benign acute childhood myositis were much higher in influenza B infection than in influenza A infections and boys are affected more commonly.

## References

- Glezen WP. Consideration of the risk of influenza in children and indications for prophylaxis. *Rev Infect Dis* 1980;2:408-20.
- Cate TR. Clinical manifestations and consequences of influenza. *Am J Med* 1987; 82:15-9.
- Douglas RG Jr. Influenza: the disease and its complications. *Hosp Pract* 1976;11:43-50.
- Lundberg A. Myalgia cruris epidemica. *Acta Paediatr* 1957; 46:18-31.
- Middleton PJ, Alexander RM, Szymanski MT. Severe myositis during recovery from influenza. *Lancet* 1970;2:533-5.
- Dietzman DE, Schaller JG, Ray CG, Reed ME. Acute myositis associated with influenza B infection. *Pediatrics* 1976;57: 255-8.
- Farrell MK, Partin JC, Bove KE. Epidemic influenza myopathy in Cincinnati in 1977. *J Pediatr* 1980;96:545-51.
- Ruff RL, Secrist D. Viral studies in benign acute childhood myositis. *Arch Neurol* 1982;39:261-3.
- Buchta RM. Myositis and influenza. *Pediatrics* 1977;60:761-2.
- Mejlszenkier JD, Safran AP, Healy JJ, Embree L, Ouellette EM. The myositis of influenza. *Arch Neurol* 1973;29:441-3.
- Antony JH, Procopis PG, Ouverier RA. Benign acute childhood myositis. *Neurology* 1979;29:1068-71.
- O'Reilly C, Gill D, Dockeray S. Acute transient myositis of childhood. *Ir J Med Sci* 1983;152:387-9.
- McKinlay IA, Mitchell I. Transient acute myositis in childhood. *Arch Dis Child* 1976;51:135-7.
- Karpathios T, Kostaki M, Drakonaki S, Garoufi A, Siahaidou S, Spirou N, et al. An epidemic with influenza B virus causing benign acute myositis in ten boys and two girls. *Eur J Pediatr* 1995;154:334-6.
- Meibalane R, Sedinak GV, Sasidharan P, Garg P, Grausz JP. Outbreak of influenza in a neonatal intensive care unit. *J Pediatr* 1977;91:974-6.
- Chang LY, Lee PI, Lin YJ, Chiu HH, Huang LM, Lee CY. Influenza B virus infection associated with shock in a two-month-old infant. *J Formos Med Assoc* 1996;95:703-5.
- Price DA, Postlethwaite RJ, Longson M. Influenza virus A2 infections presenting with febrile convulsions and gastrointestinal symptoms in young children. *Clin Pediatr* 1976;15:361-7.
- Mackay MT, Kornberg AJ, Shield LK, Dennett X. Benign acute childhood myositis: laboratory and clinical features. *Neurology* 1999;53:2127-31.
- DiBona FJ, Morens DM. Rhabdomyolysis associated with influenza A: report of a case with unusual fluid and electrolyte abnormalities. *J Pediatr* 1977;91:943-5.
- Morgensen JL. Myoglobinuria and renal failure associated with influenza. *Ann Intern Med* 1974;80:362-3.
- Kessler HA, Trenholme GM, Harris AA, Levin S. Acute myopathy associated with influenza A/Texas/1/77 infection. Isolation of virus from a muscle biopsy specimen. *JAMA* 1980; 243:461-2.
- Gamboa ET, Eastwood AB, Hays AP, Maxwell J, Penn AS. Isolation of influenza virus from muscle in myoglobinuric polymyositis. *Neurology* 1979;29:1323-35.
- Greco TP, Askenase PW, Kashgarian M. Postviral myositis: myxovirus-like structures in affected muscle. *Ann Intern Med* 1977;86:193-4.
- Servidei S, Miranda AF, Gamboa ET. Infectivity of influenza B virus in cultured human muscle. *Acta Neuropathologica* 1987; 73:67-76.
- Shaw MW, Choppin PW. Studies on the synthesis of the influenza B virus NB glycoprotein. *Virology* 1984;139:178-84.
- Betakova T, Nermut MV, Hay AJ. The NB protein is an integral component of the membrane of influenza B virus. *J Gen Virol* 1996;77:2689-94.